



## CASE REPORT

### *Comprehensive Nonextraction Treatment for An Adult. Skeletal Class I, Severe Right Side Anterior Crossbite*

*Diana C. Fong, D.D.S.  
 Oakland, CA*

*Dr. Fong graduated from the University of Southern California School of Dentistry in 1989. She began her orthodontic studies in 1995 with the AAGO series of courses and has been a member of GOOD Seminars from 1996 to present. Dr. Fong completed the BioBloc Mini-Residency with Dr. William Hang in 2007. She practices in Oakland, California with her husband, Stephen Lee, who is also a general dentist, and they have two children Crystal and Claudia.*

#### LEARNING OBJECTIVES

- Crozat Gang up and Kick Back Mechanics
- Techniques to correct a crossbite
- Dr. Mulligan's Mechanics
- RM Lock and fixed mechanics
- Patience

#### INTRODUCTION


A 36-year-old female presented with a chief complaint of crowded anterior teeth. Several dentists informed the patient that extractions were a prerequisite to any cosmetic or orthodontic treatment. She did not reconsider orthodontic treatment until her daughter was treated with Crozats in Phase I. Her medical history revealed no health problems. Teeth #7 and #8, which were in crossbite, developed 7mm pockets prior to orthodontic treatment that resolved to 3mm after the anterior teeth were uncrowded.

#### DIAGNOSIS

Class I Skeletal, Class II dental, neutral growth direction. The posterior airway space is 10mm. (Fig. 1) The patient has good oral posture and no TMJ/TMD signs or symptoms. She has moderate occlusal wear on her molars and incisor teeth due to the malocclusion. Periodontally, she is Type I gingivitis. Her overbite was 75%. The upper midline was shifted 2mm to the right and the lower midline was normal Her face is symmetrical. (Fig. 3)

#### TREATMENT OBJECTIVES

The main objectives were to level, align, uncrowd the anterior teeth and correct the Class II molar relationship. A non-extraction approach was used.



*Figure 1 - Beginning cephalometric tracing shows a deep bite Class I with neutral growth direction, long mandible and maxilla, large chin button.*

#### TREATMENT SEQUENCE

4/28/1999: Basic upper and lower Crozats were initially used for arch development. (Fig. 3)

1/21/2000: Auxiliaries for the right side gang-up, kick back mechanics were soldered on the appliance (1.1 Leone wire for the Class II hook, .9 Leone wire for the others); 5/16" Class II elastics were used to distalize the first molar to correct the Class II. (Fig. 4)

8/4/2000: Re-vamped appliance.

1/19/2001: Add pins to lower Crozat and added Class II hook on left side.

6/15/2001: Re-vamped upper Crozat.

7/10/2001: Added composite ledges to #6, adjusted recurves to #22-#27.

11/16/01: Added a lingual putter to #5 mesial; (Fig. 5) adjusted recurve to #8 at the gingival.

Rt. Side is Class I.

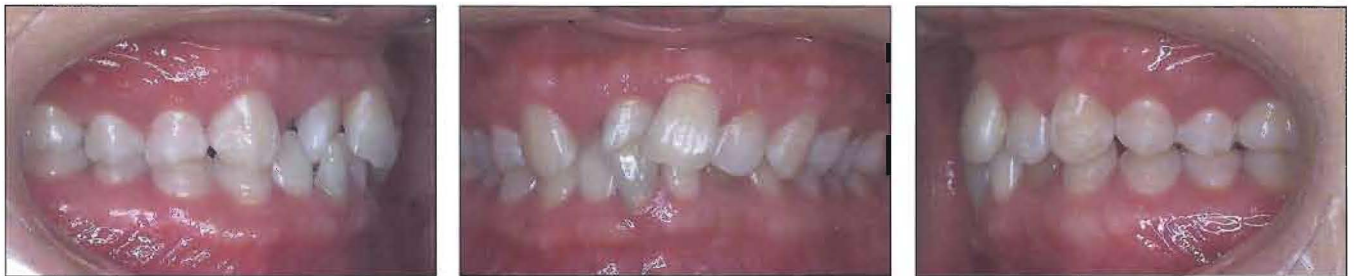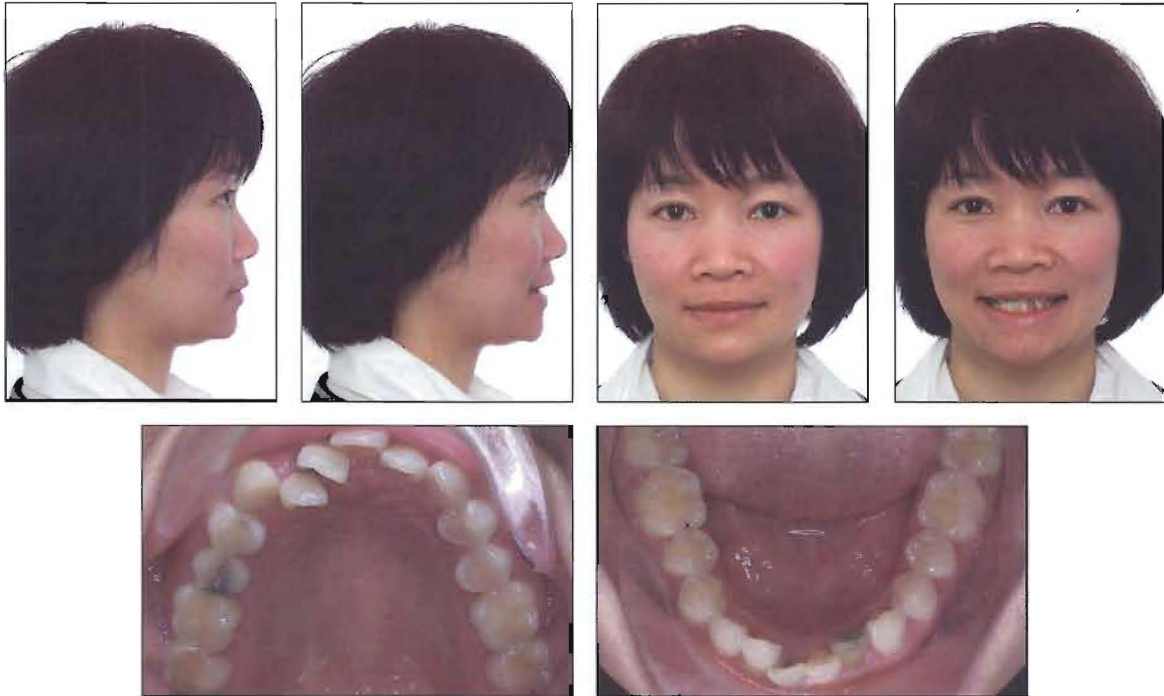


Figure 2 - Beginning facial and intraoral records showing crowded upper and lower anterior teeth with an anterior crossbite of #7 and 8.

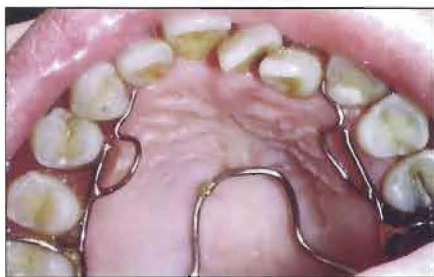

Figure 3 - Basic Upper Crozat with cuspid springs added.

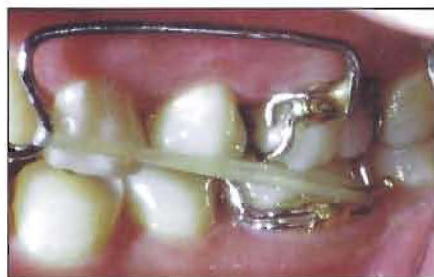

Figure 4 - Kick back mechanics. Class II elastics to a buccal Class II sectional arm were used to distalize the first molar. The opposite lingual arm was lengthened.

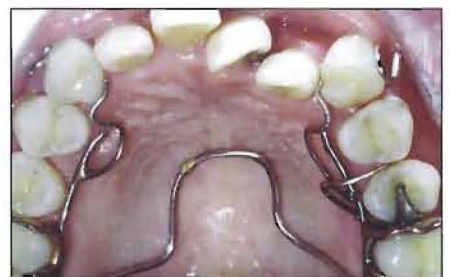

Figure 5 - Lingual putter to #5 mesial for distal movement.

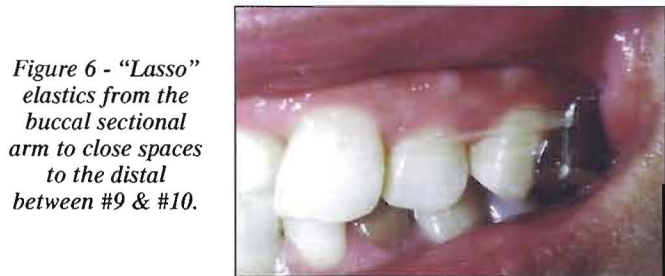


Figure 6 - "Lasso" elastics from the buccal sectional arm to close spaces to the distal between #9 & #10.

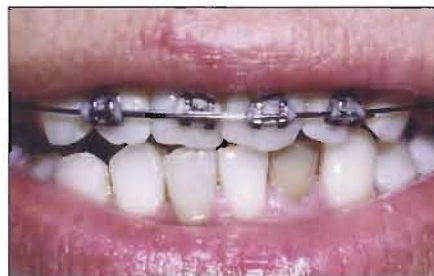

Figure 7 - .016 Copper Nitinol round sectional 2-2 piggybacked to .020 SS wire. This allowed for molar rotation and incisor alignment simultaneously.



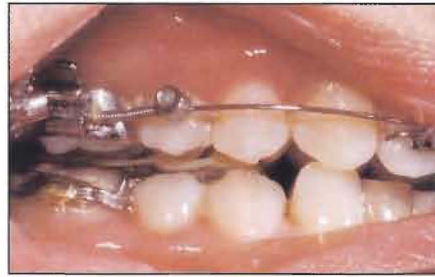

Figure 8 - RM locks were used bilaterally to compress an open coil spring 1mm for incisor advancement.

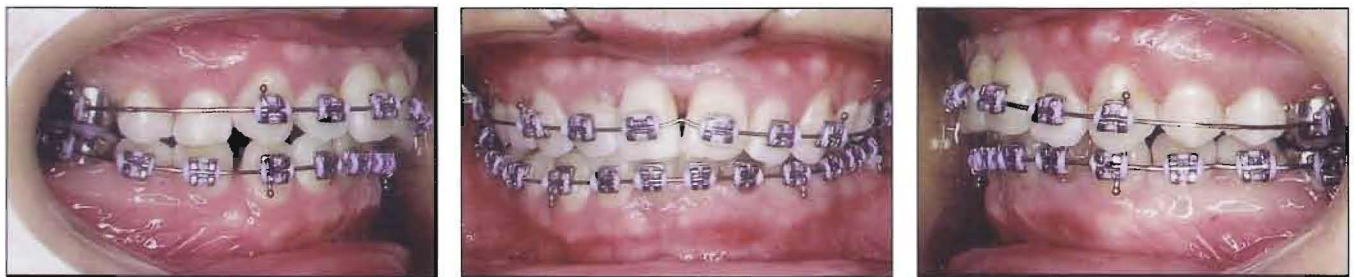
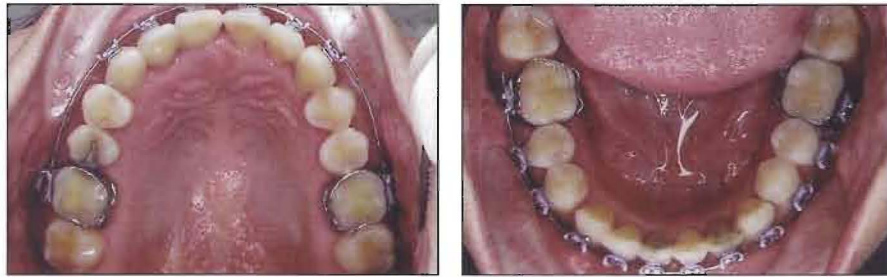
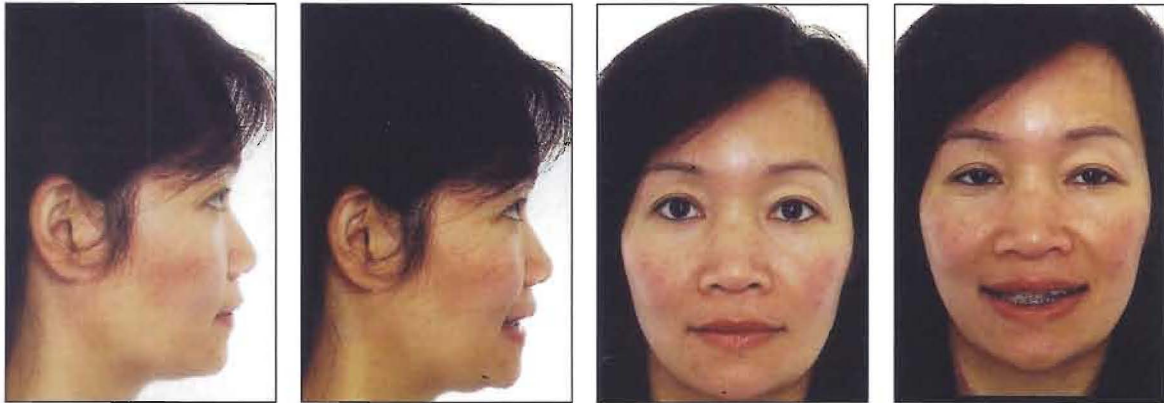Figure 9 - Progress photos. Note gable bend placed on #8 and #9 to diverge root angulations and maintain closure of contact. Dark triangle was eliminated by interproximal reduction and chain elastic 3-3.

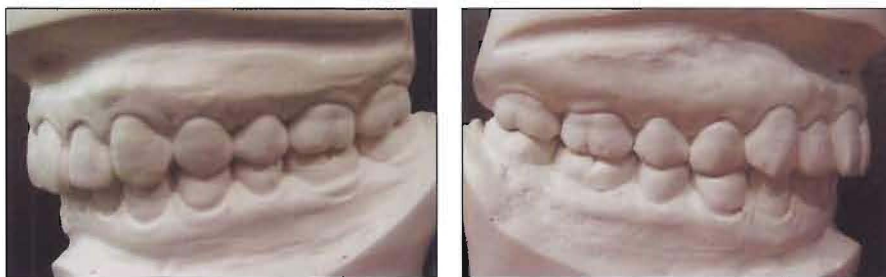


Figure 10 - Final casts show incomplete class II correction and organic occlusion in centric relation.

1/19/2002: Re-ramped appliance and added auxiliaries to #7 and #8. Pt. is wearing anterior "lasso" elastics (Fig. 6) until spaces are closed distally between #9 & #10.

4/12/2002: Band and Bracket 2 x 4, .016 Copper Nitinol round sectional 2-2 piggybacked to .020 SS wire; (Fig. 7) RM locks were then used bilaterally to compress an open coil spring 1mm for incisor advancement. (Fig. 8)

5/28/2002: Able to engage #8 into the .016 CN sectional archwire. Acrylic pads were placed on the lower Crozat at the molar area to open the bite for crossbite correction (see Fig. 8).

6/21/2002: Intrusive curve placed on .020 SS archwire. Stripped lower incisors #23-26 slightly to achieve flat contacts.

7/13/2002: Upper canines bracketed.

11/18/2002: .17 x .25 Cu Nit upper and lower archwires; engaged under #11 bracket for intrusion.

1/17/2003: Gable bend placed on #8 and #9 to diverge root angulations and close diastema. (Fig. 9)

3/27/2003: Progress records and mounted casts.

4/11/2003: Patient did not like dark triangle between-central incisors. Stripped #8 & #9, Chain elastic 3-3; patient instructed to wear Class II elastics 3/16" full time. Upper .020 SS; Lower 17 x 25 SS.

7/21/2003: Stripped 3-3 lower; lace-back lower 6-3 both sides.

9/13/2003: Tip back bends both sides; piggyback 321/123 to .020 SS archwire to avoid intrusion reciprocal.

10/10/2003: Mulligan mechanics: toe in bend was used to correct #14 rotation. Goals accomplished thus far: aligned upper centrals, reduced dark triangle, aligned the lower incisors.

11/21/2003: Rebracketed #27.

1/14/2004: Rotation wedge placed distal of #11.

1/21/2004: upper .020 SS archwire with toe in bends for rotations. Lower arch has braided 17 x 25 wire.

3/3/2004: Bracket upper bicuspid.

3/19/2004: Wires changed to 17 x 25 posted steel on the upper and .018 SS round wire to level the arch and advance the slightly recumbent lower incisors. Patient was instructed to wear Class II elastics full time, but cooperation was poor.

7/20/2004: Deband and debracket all fixed appliances.

7/21/2004: Deliver upper and lower Invisaitain retainers. Final records. Casts show incomplete class II correction. (Fig. 10)

6/8/07: 3 Year records in retention.

## RESULTS ACHIEVED

Because this case was an adult, the changes were mostly dental. The patient's profile, airway, periodontium and occlusal function were improved by uncrowding the anterior teeth, which had locked the patient's bite. The finish cephalometric tracing and superimposition show the primary changes being forward movement of the lower molars and lower incisor inclinations increasing to 95° to mandibular plane. (Fig. 11) Amazingly, there was no root resorption or bone loss associated with this patient's complete orthodontic treatment over a 5-year period (appointments were spotty at times due to the patient's travel obligations). This fact can be attributed to the gentle forces produced by the Crozat appliances and the patient's meticulous oral hygiene. The Class II dental molars and cuspids were partially corrected during treatment but the corrections didn't hold, due in part to the upper molar

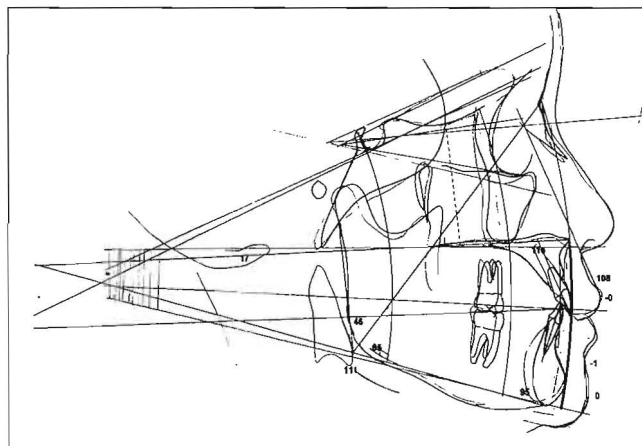
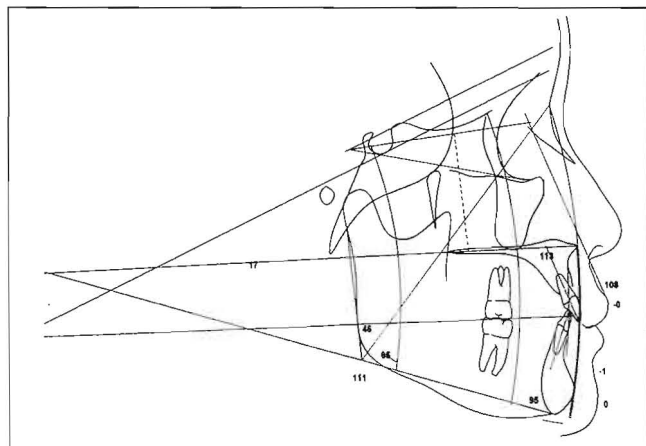
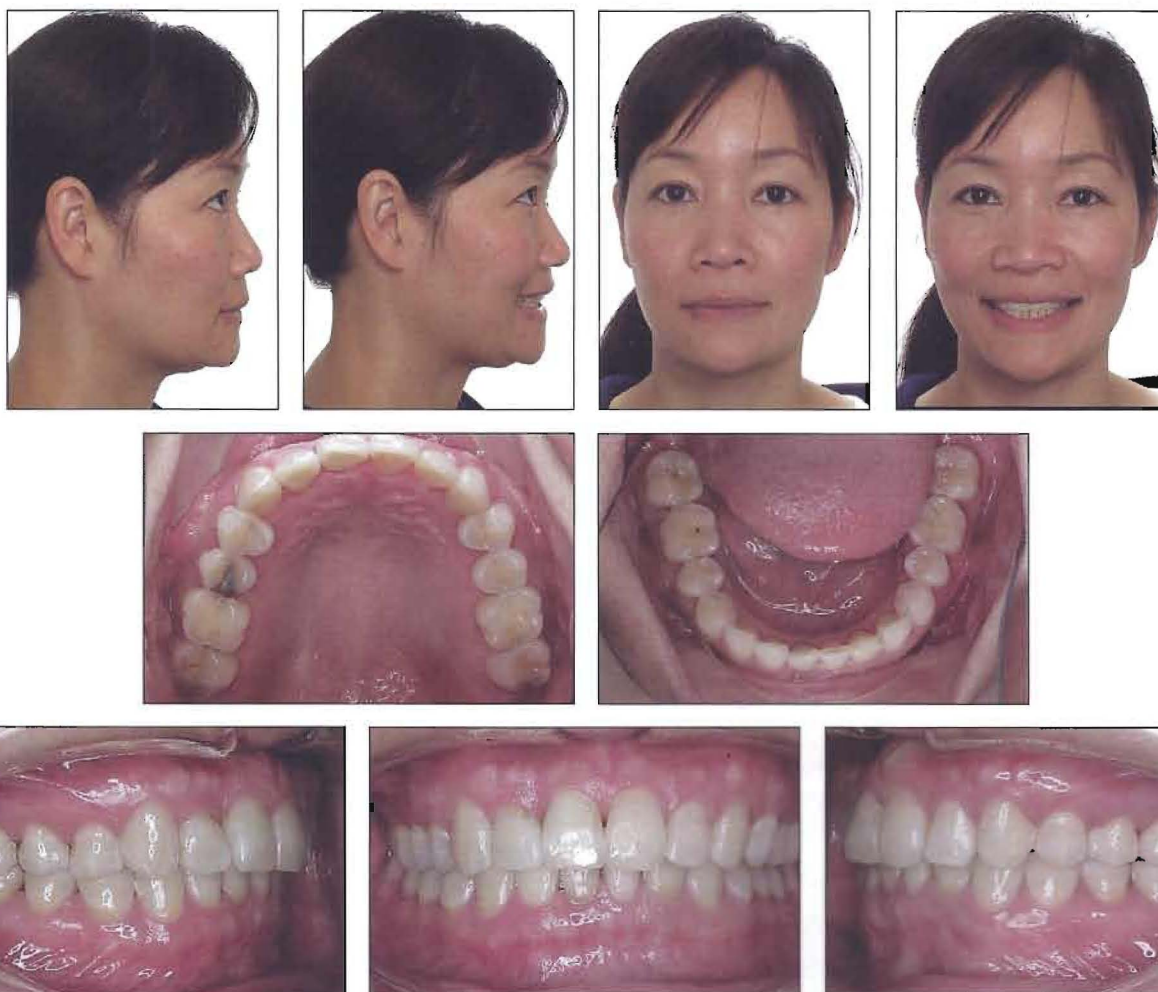

Figure 11 - The finish cephalometric tracing (a) and superimposition (b) show the primary changes being forward movement of the lower molars and lower incisor inclinations increasing to 95° to mandibular plane.





*Figure 12 Facial and intraoral photos 3 years after finish of treatment. After 3 months of full time wear, the patient decided to wear her retainers only at night. Note the minor relapse on tooth #26.*

rotations. However, the patient had an organic occlusion in centric relation at completion and in retention. She has had no complaints of TMJ/TMD disorders prior, during, or after treatment. After 3 months of full time wear, the patient decided to wear her retainers every night. There was a minor relapse on tooth #26 as shown in the 3-year follow up. (Fig. 12)

The patient is very happy with her orthodontic treatment and her gorgeous smile and wishes to the GOOD Study Club members for their support and enthusiasm during her visits to Walnut Creek.

#### ACKNOWLEDGEMENTS

To my father and mother for their faith and love.

Dr. Winston Bowman, my first mentor who introduced me to the Crozat and the AAGO.

Dr. Jack Hockel and my colleagues from GOOD I and GOOD II who, without whose encouragement and constant

support I would not have had the courage to pursue orthodontics, dentofacial orthopedics, and Biobloc orthotropics .

Craig Deutermann, my #1 Crozat technician, for the many phone calls and advice on "how to" and "how not to."

Carl Meyer, ESQ. for the professional consultations, friendship, and for insisting I publish.

I was blessed to train with some "famous" operators: the late Walt Brehm, Bill Nequette and John Baranko; and I am always rejuvenated when I see the senior Crozat dentists at the AAGO-Lawrence Willis, Tom Paison, Doyle Beavers, Bob Katsev, Stan Hess practicing and so enthusiastic about their profession.

And my family for their patience and generosity in allowing me to travel all over the country in pursuit of knowledge to advance my orthodontic education.